



## PATIENT

Didy Otero

## SPECIES

Feline

## BREED

DSH

## SEX

FS

## AGE

11yr

## WEIGHT

4.2lb

## INTERPRETED BY

R. McKenzie Daniel,  
DVM, DABVP  
(Canine and Feline)

## IMAGING PERFORMED BY

Dr. Gabriel Ferrer  
DVM

## HOSPITAL NAME

Pulse Pet Ultrasound  
Services

## REFERRING VET

Dra. Marilyn Davila

## INVOICE

22321

## DATE

12/22/2025

## PRESENTING CLINICAL SIGNS

Presented as a referral for a thoracic non cardiac ultrasound to evaluate thoracic mass. Pt presented to rDVM with hx of lethargy and inappetence that started 7 days ago. No v/d/c/s. Vaccines up to date, including the Leukemia vaccine. Patient is indoors. Tender abdomen on physical exam. No change in diet.

Abnormal PE/Chem/CBC/UA Results: Radiographs and report attached as supporting documents  
Bloodwork attached

## ULTRASONOGRAPHIC EXAMINATION OF THE THORAX

A homogenous, primarily spherical appearing mass vs lymph node was present in the cranial thorax to cranial mediastinal space measuring ~ 3 cm in diameter. Mild associated cranial thoracic to cranial mediastinal effusion was present.

Mid to cranial left and right aerated lung exhibited comet tail artifact.

Subjective normal cardiac structure and function.

No overt pericardial effusion.

## ULTRASONOGRAPHIC FINDINGS

### Primary

- Cranial thoracic / mediastinal mass vs lymph node.
- Mid to cranial left/ right pulmonary comet tail artifact
- Minor pleural / mediastinal effusion

## INTERPRETATION OF THE FINDINGS & FURTHER RECOMMENDATIONS

Correlation with pending mass vs lymph node cytology +/- C/S is recommended. If possible, thoracic CT may be considered for further clarification of the cranial mediastinum and mid to cranial lung.



**PATIENT**

Didy Otero

**SPECIES**

Feline

**BREED**

DSH

**SEX**

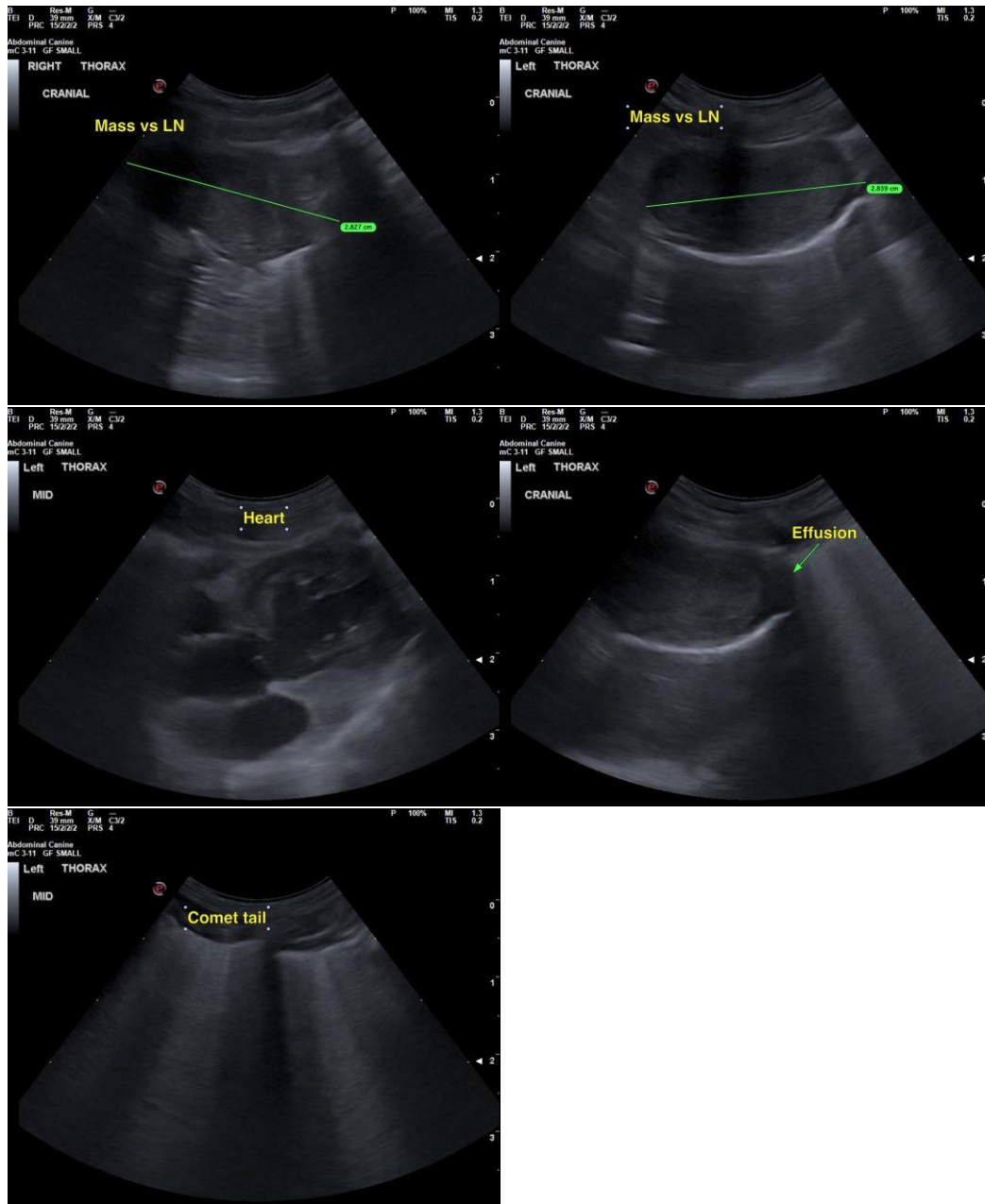
FS

**AGE**

11yr

**WEIGHT**

4.2lb



**INTERPRETED BY**

R. McKenzie Daniel,  
DVM, DABVP  
(Canine and Feline)

**IMAGING PERFORMED BY**

Dr. Gabriel Ferrer  
DVM

**HOSPITAL NAME**

Pulse Pet Ultrasound  
Services

**REFERRING VET**

Dra. Marilyn Davila

**INVOICE**  
22321

**DATE**  
12/22/2025

The information and recommendations provided are based on the images presented by the referring veterinarian/sonographer. No evaluation can be communicated regarding pathology that was not visible in the image/video clips provided.

Thank you for this referral. If the clinical or image interpretation does not parallel your findings or if I can be of any further assistance, please contact me.

R. McKenzie Daniel, DVM, DABVP (Canine/Feline Practice)  
[info@sonopath.com](mailto:info@sonopath.com)



## PATIENT

Didy Otero

## SPECIES

Feline

## BREED

DSH

## SEX

FS

## AGE

11yr

## WEIGHT

4.2lb

## INTERPRETED BY

R. McKenzie Daniel,  
DVM, DABVP  
(Canine and Feline)

## IMAGING PERFORMED BY

Dr. Gabriel Ferrer  
DVM

## HOSPITAL NAME

Pulse Pet Ultrasound  
Services

## REFERRING VET

Dra. Marilyn Davila

## INVOICE

22321

## DATE

12/22/2025